

Chapter 01: Introduction to Preliminary Diagnosis of Oral Lesions Test Bank

MULTIPLE CHOICE

1. Which of the following would be described as a segment that is part of the whole?
 - A. Bulla
 - B. Vesicle
 - C. Lobule
 - D. Pustule

ANS: C

	Feedback
A	A bulla is a large, elevated lesion that contains serous fluid and may look like a blister.
B	A vesicle is a small, elevated lesion that contains serous fluid.
C	Correct! A lobule is described as a segment or lobe that is part of a whole.
D	Pustules are circumscribed elevations containing pus.

REF: Vocabulary, Clinical Appearance of Soft Tissue Lesions, page 1

OBJ: 1

2. A lesion with a sessile base is described as:
 - A. an ulcer.
 - B. stemlike.
 - C. pedunculated.
 - D. flat and broad.

ANS: D

	Feedback
A	An ulcer is a break in the surface epithelium.
B	A stemlike lesion is referred to as <i>pedunculated</i> .
C	A pedunculated lesion is stemlike or stalk-based (similar to a mushroom).
D	Correct! <i>Sessile</i> describes the base of a lesion that is flat and broad.

REF: Vocabulary, Clinical Appearance of Soft Tissue Lesions, page 1

OBJ: 1

3. Which one of the following is *not* diagnosed through clinical appearance?
 - A. Mandibular tori
 - B. Fordyce granules
 - C. Black hairy tongue
 - D. Compound odontoma

ANS: D

	Feedback
A	Mandibular tori are identified clinically as areas of exostosis on the lingual

	aspects of mandibular premolars.
B	Fordyce granules are yellow clusters of ectopic sebaceous glands that are diagnosed through clinical appearance.
C	Black hairy tongue is diagnosed clinically. The filiform papillae on the dorsal tongue elongate and become brown or black. Causes include tobacco, alcohol, hydrogen peroxide, chemical rinses, antibiotics, and antacids.
D	Correct! The compound odontoma is initially identified radiographically as a radiopaque area in which tooth structure can be identified. There is no clinical component.

REF: Radiographic Diagnosis, page 9 OBJ: 3

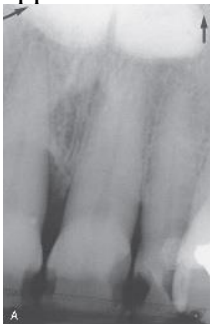4. Another name for geographic tongue is:
- A. median rhomboid glossitis.
 - B. benign migratory glossitis.
 - C. fissured tongue.
 - D. black hairy tongue.

ANS: B

Feedback	
A	Research suggests that median rhomboid glossitis is associated with a chronic fungal infection from <i>Candida albicans</i> . Sometimes the condition resolves with antifungal therapy.
B	Correct! Benign migratory glossitis is another name for geographic tongue.
C	Fissured tongue is seen in 5% of the population. It is a variant of normal. Genetic factors are probably associated with the condition.
D	Black hairy tongue is caused by a reaction to chemicals, tobacco, hydrogen peroxide, or antacids. The filiform papillae on the dorsal tongue become elongated and are dark brown to black.

REF: Geographic Tongue, page 25 OBJ: 7

5. This bony hard radiopaque structure in the midline of the hard palate is genetic in origin and inherited in an autosomal dominant manner. The diagnosis is made through clinical appearance.



You suspect a:

- A. palatal cyst.
- B. torus palatinus.
- C. mixed tumor.
- D. ranula.

ANS: B

	Feedback
A	A palatal cyst is radiolucent and not diagnosed through clinical appearance.
B	Correct! A torus palatinus is developmental and bony hard and is found on the midline of the palate. Diagnosis is made on the basis of clinical appearance.
C	A mixed tumor or pleomorphic adenoma is a benign tumor of salivary gland origin, found unilaterally off the midline of the hard palate. It is composed of tumor tissue that is not bony hard to palpation.
D	<i>Ranula</i> is a term used for a mucocele-like lesion that forms unilaterally on the floor of the mouth.

REF: Torus Palatinus, page 32

OBJ: 4

6. The gray-white opalescent film seen on the buccal mucosa of 85% of black adults is a variant of normal that requires no treatment and is called:
- A. linea alba.
 - B. leukoedema.
 - C. leukoplakia.
 - D. white sponge nevus.

ANS: B

	Feedback
A	Linea alba is a “white line” that extends anteroposteriorly on the buccal mucosa along the occlusal plane. It is most prominent in patients who have a clenching or grinding habit.
B	Correct! Leukoedema is a diffuse opalescence most commonly seen on the buccal mucosa in black individuals.
C	<i>Leukoplakia</i> is a clinical term for a white lesion, the cause of which is unknown.
D	White sponge nevus is a genetic (autosomal dominant) trait. Clinically, it is characterized by a soft white, folded (or <i>corrugated</i>) oral mucosa. A thick layer of keratin produces the whitening.

REF: Leukoedema, page 24

OBJ: 8

7. Which one of the following conditions would most likely respond to therapeutic diagnosis?
- A. Angular cheilitis
 - B. Amelogenesis imperfecta
 - C. Paget disease
 - D. Stafne bone cyst

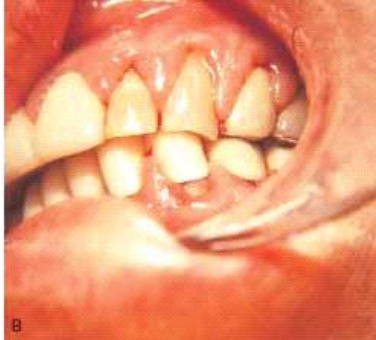ANS: A

	Feedback
A	Correct! Angular cheilitis most commonly responds to antifungal therapy once nutritional deficiencies have been ruled out.
B	Amelogenesis imperfecta is a genetic condition associated with abnormal development of the enamel.
C	Paget disease is a chronic metabolic bone disease. A highly elevated serum

	alkaline phosphatase level contributes significantly to the diagnosis.
D	A Stafne bone cyst is determined through surgical diagnosis in which entrapped salivary gland tissue is identified.

REF: Therapeutic Diagnosis, page 20 OBJ: 3

8. The gingival enlargement in this patient was caused by a calcium channel blocker.



Which one of the following would likely be the cause?

- A. Dilantin
- B. Nifedipine
- C. Quinidine
- D. Clozapine

ANS: B

Feedback	
A	Dilantin is an anticonvulsant used to prevent or control seizures.
B	Correct! Nifedipine is a calcium channel blocker.
C	Quinidine is an antiarrhythmic agent used to treat cardiac arrhythmias.
D	Clozapine is an antipsychotic used in the management of psychotic symptoms in schizophrenia.

REF: Historical Diagnosis, Figure 1-39, page 18

OBJ: 3

9. Radiographic features, including the cotton-wool effect and hypercementosis, are especially helpful in the diagnosis of:
- A. Paget disease.
 - B. dentinogenesis imperfecta.
 - C. anemia.
 - D. diabetes.

ANS: A

Feedback	
A	Correct! Paget disease is a chronic metabolic bone disease. Radiographically, the cotton-wool effect and hypercementosis are characteristic features.
B	Dentinogenesis imperfecta is a genetic condition involving a defect in the development of dentin.
C	Anemia, a decrease in red blood cells, requires blood tests to determine the etiologic factors.
D	Diabetes is a chronic disorder of carbohydrate metabolism characterized by

	abnormally high blood glucose levels.
--	---------------------------------------

REF: Laboratory Diagnosis, Figure 1-41, pages 17, 19

OBJ: 3

10. In internal resorption, the radiolucency seen radiographically is usually:
- A. well circumscribed.
 - B. diffuse.
 - C. multilocular.
 - D. unilocular.

ANS: B

Feedback	
A	<i>Well circumscribed</i> describes borders that are specifically defined. Exact margins of the lesion are identified.
B	Correct! Diffuse borders are ill defined, making it impossible to detect the exact parameters of the lesion. Therefore treatment is more difficult.
C	<i>Multilocular</i> has also been described as resembling “soap bubbles”; lobes seem to fuse together to make up the lesion. This term has been used to describe the odontogenic keratocyst.
D	<i>Unilocular</i> means having one compartment or unit that is well defined. This term is often used to describe the radicular cyst.

REF: Vocabulary, Radiographic Terms Used to Describe Lesions in Bone, page 5

OBJ: 1

11. Which one of the following is diagnosed through clinical appearance?
- A. Fordyce granules
 - B. Unerupted mesiodens
 - C. Periapical cemento-osseous dysplasia
 - D. Traumatic bone cyst

ANS: A

Feedback	
A	Correct! Fordyce granules are diagnosed on the basis of their clinical appearance. They are ectopic sebaceous glands seen on the lips and buccal mucosa. Clinically, they appear as yellow lobules in clusters and are considered a variant of normal.
B	Unerupted mesiodens requires a radiograph for diagnosis.
C	Periapical cemento-osseous dysplasia requires a radiograph, specific patient history, and a pulp test to evaluate tooth vitality.
D	Traumatic bone cyst requires a radiograph and surgical intervention to establish a diagnosis.

REF: Clinical Diagnosis, page 7 | Fordyce Granules, page 22

OBJ: 3

12. Retrocuspid papillae are located on the:
- A. palate.
 - B. floor of the mouth.
 - C. gingival margin of the lingual aspect of mandibular cuspids.

D. canine eminence.

ANS: C

	Feedback
A	Retrocuspid papillae are not located on the palate.
B	Retrocuspid papillae are not located on the floor of the mouth.
C	Correct! Retrocuspid papillae are located on the gingival margin of the lingual aspect of mandibular cuspids.
D	Retrocuspid papillae are not located on the canine eminence.

REF: Retrocuspid Papilla, page 23 OBJ: 3

13. Which one of the following is *not* considered a variant of normal?
- A. Fordyce granules
 - B. Leukoedema
 - C. Linea alba
 - D. Pyogenic granuloma

ANS: D

	Feedback
A	Fordyce granules are seen in more than 80% of adults over 20 years of age and are considered a variant of normal.
B	Leukoedema is observed in about 85% of black individuals and is considered a variant of normal.
C	Linea alba is located on the buccal mucosa along the occlusal plane of the teeth. It is most prominent in patients who have a clenching or bruxism habit. It is so common that it is considered a variant of normal.
D	Correct! Pyogenic granuloma is a reactive inflammatory response to injury. It is not a variant of normal.

REF: Box 1-1, Case Study, page 21 | Variants of Normal, pages 22-24
OBJ: 6

14. When antifungal therapy is used to treat angular cheilitis, which diagnostic process is being applied?
- A. Microscopic
 - B. Laboratory
 - C. Surgical
 - D. Therapeutic

ANS: D

	Feedback
A	Microscopic diagnosis requires a biopsy.
B	Laboratory diagnosis involves the use of clinical laboratory tests, including blood chemistries and urinalysis.
C	Surgical diagnosis requires surgical intervention.
D	Correct! Therapeutic diagnosis is used here in the treatment and management of angular cheilitis, which is most commonly a fungal condition. A careful patient

history should be obtained to rule out a contributory nutritional deficiency.

REF: Therapeutic Diagnosis, page 20 OBJ: 3

15. A lesion with a stemlike base is described as:
- A. sessile.
 - B. macular.
 - C. pedunculated.
 - D. lobulated.

ANS: C

	Feedback
A	A sessile base is broad and flat.
B	A macular lesion is flat, does not protrude, and is distinguished by its color. A freckle is an example of a macule.
C	Correct! <i>Pedunculated</i> means the lesion has a stemlike or stalklike base similar to that of a mushroom.
D	<i>Lobulated</i> means the lesion consists of lobules making up the whole.

REF: Vocabulary, Clinical Appearance of Soft Tissue Lesions, page 1
OBJ: 8

16. A small, circumscribed lesion, usually less than 1 cm in diameter, that is elevated or protrudes above the surface of normal surrounding tissue is a:
- A. papule.
 - B. macule.
 - C. vesicle.
 - D. bulla.

ANS: A

	Feedback
A	Correct! A papule is defined as a small circumscribed lesion, usually less than 1 cm in diameter, that is elevated or protrudes above the surface of normal surrounding tissue.
B	A macule is flat and does not protrude above the surface of normal tissue.
C	A vesicle is elevated and contains serous fluid.
D	A bulla is elevated, contains serous fluid, and looks like a blister.

REF: Vocabulary, Clinical Appearance of Soft Tissue Lesions, page 1
OBJ: 1

17. Which one of the following is considered a genetic/inherited disorder?
- A. Linea alba
 - B. Amelogenesis imperfecta
 - C. Necrotizing ulcerative gingivitis
 - D. Internal resorption

ANS: B

	Feedback
A	Linea alba is a variant of normal characterized by the white line that extends anteroposteriorly on the buccal mucosa, along the occlusal plane.
B	Correct! Amelogenesis imperfecta represents a group of inherited conditions affecting the enamel of teeth.
C	Necrotizing ulcerative gingivitis is an ulcerating gingival condition caused by anaerobic bacteria.
D	Internal resorption is usually associated with an inflammatory response in the pulp.

REF: Historical Diagnosis, page 16 OBJ: 3

18. Ectopic geographic tongue can be found:
- A. on the lateral border of the tongue.
 - B. within bone.
 - C. on mucosal surfaces other than the tongue.
 - D. on the dorsal tongue.

ANS: C

	Feedback
A	Geographic tongue may be seen on any surface of the tongue, including the lateral borders.
B	Ectopic geographic tongue is a mucosal condition and is unrelated to the bone.
C	Correct! Ectopic geographic tongue is also called <i>stomatitis areata migrans</i> and is found on mucosal surfaces other than the tongue.
D	Geographic tongue may be seen on any mucosal surface and is commonly seen on the dorsal surface of the tongue.

REF: Geographic Tongue, page 25 OBJ: 7

19. A Stafne bone cyst contains:
- A. salivary gland tissue.
 - B. an empty void.
 - C. inflammatory cells.
 - D. an epithelium-lined cyst containing serous fluid.

ANS: A

	Feedback
A	Correct! Stafne bone cyst is a developmental invagination in the lingual aspect of the mandible that is filled with salivary gland tissue.
B	An empty void describes the contents of a traumatic bone cyst.
C	A Stafne bone cyst has no inflammatory response. It is developmental and requires no treatment.
D	A Stafne bone cyst is not a true cyst and does not have an epithelial lining. It contains normal salivary gland tissue.

REF: Surgical Diagnosis, page 20 OBJ: 3

20. Which papillae are elongated in the condition called black hairy tongue?
- A. Circumvallate
 - B. Foliate
 - C. Filiform
 - D. Fungiform

ANS: C

	Feedback
A	Circumvallate papillae on the posterior dorsal tongue do not elongate.
B	Foliate papillae are located on the posterior lateral borders of the tongue. They are vertical, slightly exophytic folds of tissue located in the same area as the lingual lymphoid tissue (lingual tonsils) and do not elongate.
C	Correct! The filiform papillae are composed primarily of keratin and are the papillae that elongate in black hairy tongue.
D	Fungiform papillae on the dorsal areas do not elongate.

REF: Hairy Tongue, page 26

OBJ: 3

21. Diagnosis of anemia is best accomplished through:
- A. laboratory tests.
 - B. evaluation of the color of the gingiva.
 - C. bleeding on probing.
 - D. the patient's medical history.

ANS: A

	Feedback
A	Correct! Laboratory blood tests provide the best information with which to diagnose anemia.
B	Although the color of the gingiva may be a clinical sign, a diagnosis of anemia, or more specifically the type of anemia, must be made through laboratory testing.
C	Bleeding on probing is not useful in the diagnosis of anemia.
D	The patient's medical history may be helpful in the diagnosis of anemia, but it is only contributory. The final diagnosis comes from appropriate laboratory tests.

REF: Laboratory Diagnosis, page 17

OBJ: 3

22. A radiolucency that "scallops around the roots of teeth" is often used to describe a:
- A. traumatic bone cyst.
 - B. Stafne bone cyst.
 - C. lingual mandibular bone concavity.
 - D. median palatine cyst.

ANS: A

	Feedback
A	Correct! <i>Scalloping around the roots</i> is a term often used to describe the radiographic appearance of a traumatic bone cyst.
B	A Stafne bone cyst usually presents as an oval radiolucency anterior to the angle

	of the ramus and inferior to the mandibular canal.
C	A lingual mandibular bone concavity is the same as a Stafne bone cyst.
D	A median palatine cyst is a developmental cyst that presents as a unilocular radiolucency found in the midline of the hard palate.

REF: Vocabulary, Radiographic Terms Used to Describe Lesions in Bone, page 5

OBJ: 3

23. When geographic tongue occurs on the dorsal tongue, the erythematous areas may be appropriately described as:
- A. inflamed.
 - B. depapillated.
 - C. allergic.
 - D. fungal.

ANS: B

Feedback	
A	The erythematous areas seen on the dorsal tongue in geographic tongue are not caused primarily by inflammation.
B	Correct! In geographic tongue, the erythematous areas on the dorsal tongue are devoid of filiform papillae and therefore are appropriately described as depapillated.
C	Geographic tongue is not an allergic reaction.
D	Geographic tongue is not a fungal infection.

REF: Geographic Tongue, page 25 OBJ: 7

24. It has been suggested that *Candida albicans* is associated with which one of the following?
- A. Median rhomboid glossitis
 - B. Linea alba
 - C. Leukoedema
 - D. Retrocuspid papillae

ANS: A

Feedback	
A	Correct! Research has suggested that median rhomboid glossitis may be associated with <i>Candida albicans</i> .
B	Linea alba is a variant of normal.
C	Leukoedema is a variant of normal.
D	Retrocuspid papillae are developmental and found on the gingiva of the lingual aspect of mandibular canine teeth.

REF: Median Rhomboid Glossitis, page 24 OBJ: 7

25. Which term is used to describe a lesion with borders that are specifically defined and in which one can see the exact margins and extent of the lesion?
- A. Unilocular
 - B. Well circumscribed

- C. Diffuse
- D. Multilocular

ANS: B

	Feedback
A	<i>Unilocular</i> means having one compartment or unit that is well defined (as in a radicular cyst).
B	Correct! <i>Well circumscribed</i> defines a lesion with borders that are specifically defined and in which one can see the exact margins and extent of the lesion.
C	<i>Diffuse</i> describes a lesion with borders that are not well defined.
D	Multilocular lesions are described radiographically as resembling “soap bubbles” (i.e., a lesion with many lobes beyond the confines of one distinct area).

REF: Vocabulary, Radiographic Terms Used to Describe Lesions in Bone, page 5
 OBJ: 1

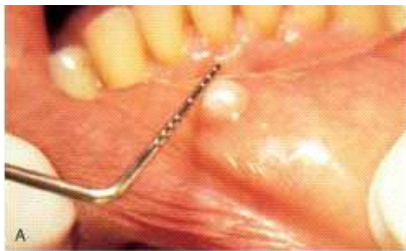26. Fordyce granules:
- A. are ectopic sebaceous glands.
 - B. are seen on the dorsal tongue.
 - C. require antibiotic treatment.
 - D. are lesions that require biopsy for diagnosis.

ANS: A

	Feedback
A	Correct! Fordyce granules are ectopic sebaceous glands.
B	Fordyce granules are seen on the buccal and labial mucosa, not the dorsal tongue.
C	Fordyce granules require no treatment.
D	Fordyce granules are diagnosed through clinical appearance. Biopsy is not necessary.

REF: Fordyce Granules, page 22 OBJ: 4

27. The base of this lesion would be described as:



- A. pedunculated.
- B. lobule.
- C. bulla.
- D. sessile.

ANS: D

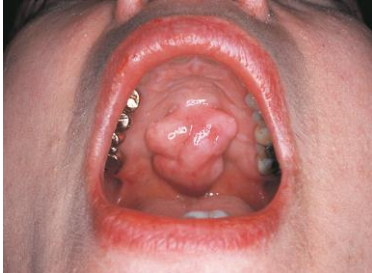	Feedback
--	----------

A	A pedunculated lesion has a stemlike base similar to that of a mushroom stem.
B	A lobule is a segment or lobe that is part of the whole.
C	A bulla usually contains serous fluid and looks like a blister.
D	Correct! The base of this lesion is sessile, or broad and flat.

REF: Vocabulary, Clinical Appearance of Soft Tissue Lesions, Figure 1-5A, pages 1, 3

OBJ: 1

28. This torus palatinus would be described as:



- A. bullous.
- B. papular.
- C. lobulated.
- D. nodular.

ANS: C

	Feedback
A	Bullous lesions contain serous fluid and look like blisters.
B	A papule is a soft tissue lesion that is elevated above the surface of normal surrounding tissue.
C	Correct! This torus palatinus is lobulated (i.e., lobes that are fused together).
D	A nodule is a palpable solid lesion found in soft tissue.

REF: Vocabulary, Clinical Appearance of Soft Tissue Lesions, Figure 1-1, page 2

OBJ: 1

29. Another name for an amalgam tattoo is a:

- A. melanoma.
- B. focal argyrosis.
- C. nevus.
- D. multiple myeloma.

ANS: B

	Feedback
A	A melanoma is a malignant tumor.
B	Correct! Focal argyrosis is a synonym for amalgam tattoo.
C	A nevus is a benign overgrowth of melanocytes.
D	Multiple myeloma is a malignant proliferation of plasma cells.

REF: Clinical Diagnosis, page 9

OBJ: 2

30. Which one of the following is *not* apparent in leukoedema?

- A. Intracellular edema in the spinous cells
- B. Acanthosis of the epithelium
- C. Generalized opalescence of the buccal mucosa
- D. A white diffuse material on the buccal mucosa that can be wiped off

ANS: D

	Feedback
A	Intracellular edema in the spinous cells is found in leukoedema.
B	Acanthosis of the epithelium is found in leukoedema.
C	Generalized opalescence of the buccal mucosa is seen in leukoedema.
D	Correct! A white diffuse material that can be wiped off is significant in diagnosing pseudomembranous candidiasis.

REF: Leukoedema, page 24

OBJ: 8

31. Which of the following best describes an elevated, 5-mm soft tissue lesion containing serous fluid?
- A. Macule
 - B. Vesicle
 - C. Lobule
 - D. Pustule

ANS: B

	Feedback
A	A macule is a flat area usually distinguished by a color different from the surrounding tissue.
B	Correct! A vesicle is a small (less than 1 cm in diameter), elevated lesion that contains serous fluid.
C	A lobule is described as a segment or lobe that is part of a whole.
D	A pustule is a circumscribed elevation containing pus.

REF: Vocabulary, Clinical Appearance of Soft Tissue Lesions, page 1

OBJ: 1

32. A lesion with a pedunculated base is best described as:
- A. an ulcer.
 - B. stemlike.
 - C. pallor.
 - D. broad and flat.

ANS: B

	Feedback
A	An ulcer is a break in the surface epithelium.
B	Correct! A stemlike lesion is referred to as <i>pedunculated</i> .
C	Pallor is a paleness of the skin or mucosal tissues.
D	<i>Broad and flat</i> describes the base of a sessile lesion.

REF: Vocabulary, Clinical Appearance of Soft Tissue Lesions, page 1

OBJ: 1

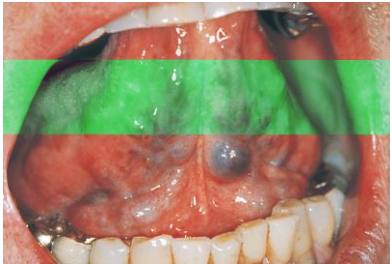
33. All of the following lesions are identified radiographically except one. Which one is the *exception*?
- A. Root resorption
 - B. Fordyce granules
 - C. Interproximal dental caries
 - D. Compound odontoma

ANS: B

	Feedback
A	Root resorption is identified radiographically when the apex of the tooth appears shortened or blunted.
B	Correct! Fordyce granules are yellow clusters of ectopic sebaceous glands that are diagnosed through clinical appearance.
C	Interproximal dental caries are seen as radiographic radiolucencies.
D	A compound odontoma is initially identified radiographically as a radiopaque area in which tooth structure can be identified.

REF: Clinical Diagnosis, page 7 | Fordyce Granules, page 22 OBJ: 3

34. These reddish-purple clusters observed on the ventral surface of the tongue and diagnosed through clinical observation are referred to as which of the following variants of normal conditions?



- A. Palatal cyst
- B. Mandibular tori
- C. Lingual varicosities
- D. Ranula

ANS: C

	Feedback
A	A palatal cyst is radiolucent and not diagnosed through clinical appearance.
B	Mandibular tori are outgrowths of hard dense bone and found on the lingual aspect of the mandible.
C	Correct! Lingual varicosities are prominent lingual veins usually observed on the ventral and lateral surfaces of the tongue.
D	<i>Ranula</i> is a term used to describe a mucocele-like lesion that forms unilaterally on the floor of the mouth.

REF: Lingual Varicosities, page 23 OBJ: 4

35. An elevated serum alkaline phosphate level, significant in the diagnosis of Paget disease, is determined from which of the following diagnostic categories?
- A. Laboratory
 - B. Therapeutic
 - C. Clinical
 - D. Surgical

ANS: A

Feedback	
A	Correct! Laboratory tests, including blood chemistries, can provide information that contributes to a diagnosis.
B	Therapeutic testing applies the principle of diagnosis based on clinical and historical information with confirmation by the response of the condition to therapy.
C	Clinical diagnosis suggests that the strength of the diagnosis comes from the clinical appearance of the lesion.
D	Surgical diagnosis is based on information about a lesion gained during surgical intervention.

REF: Laboratory Diagnosis, page 17 OBJ: 2

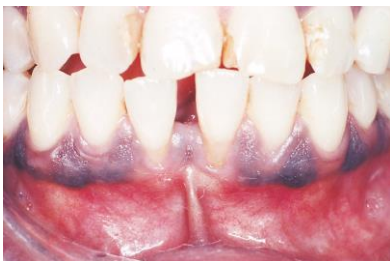36. All of the following conditions would most likely respond to therapeutic diagnosis except one. Which one is the *exception*?
- A. Angular cheilitis
 - B. Necrotizing ulcerative gingivitis
 - C. Nutritional deficiencies
 - D. Stafne bone cyst

ANS: D

Feedback	
A	Angular cheilitis commonly responds to antifungal therapy once nutritional deficiencies have been ruled out.
B	Necrotizing ulcerative gingivitis responds to hydrogen peroxide rinses.
C	Nutritional deficiencies are common conditions diagnosed by therapeutic means.
D	Correct! Stafne bone cyst, in which entrapped salivary gland tissue is identified, is diagnosed through surgical examination.

REF: Surgical Diagnosis, page 20 OBJ: 3

37. The variant of normal coloration seen on the mandibular gingival surface of this patient is referred to as:



- A. lingual varicosities.
- B. leukoedema.
- C. melanin pigmentation.
- D. linea alba.

ANS: C

	Feedback
A	Lingual varicosities are prominent lingual veins observed on the ventral and lateral surfaces of the tongue.
B	Leukoedema is a generalized opalescence imparted to the buccal mucosa.
C	Correct! Melanin pigmentation is most commonly seen in dark-skinned individuals and gives color to the oral mucosa and gingiva.
D	Linea alba is a white line that extends anteroposteriorly on the buccal mucosa along the occlusal plane of the teeth.

REF: Melanin Pigmentation, Figure 1-51, page 23

OBJ: 6

38. A clinical term for a white lesion that cannot be rubbed off and cannot be diagnosed on the basis of clinical characteristics alone is:
- A. leukoplakia.
 - B. dentinogenesis imperfecta.
 - C. erythroplakia.
 - D. squamous cell carcinoma.

ANS: A

	Feedback
A	Correct! <i>Leukoplakia</i> is a clinical term for a white lesion that cannot be rubbed off and cannot be diagnosed on the basis of clinical characteristics alone.
B	Dentinogenesis imperfecta is a genetic condition involving a defect in the development of dentin.
C	<i>Erythroplakia</i> is a clinical term for a red lesion that cannot be diagnosed on the basis of clinical features alone.
D	Squamous cell carcinoma is diagnosed by microscopic evaluation and does not refer to all white lesions that cannot be rubbed off.

REF: Microscopic Diagnosis, page 19

OBJ: 9

39. The radiographic appearance of a simple radicular cyst is best described as:
- A. coalescence.
 - B. diffuse.
 - C. multilocular.
 - D. unilocular.

ANS: D

	Feedback
A	<i>Coalescence</i> refers to the process by which parts of a whole join together, or fuse, to make one.
B	<i>Diffuse</i> describes a lesion with ill-defined borders, making it impossible to detect

	the exact parameters of the lesion.
C	A multilocular lesion has also been described as “soap bubble”–like; the lobes appear to fuse together to make up the lesion.
D	Correct! <i>Unilocular</i> means having one compartment or unit that is well defined. This term is often used to describe a radicular cyst.

REF: Vocabulary, Radiographic Terms Used to Describe Lesions in Bone, Figure 1-13, pages 5-6
 OBJ: 1

40. A pathological lesion found frequently in black women in the third decade of life and requiring a radiograph and historical data for diagnosis is:
- verrucous vulgaris.
 - necrotizing ulcerative gingivitis.
 - periapical cemento-osseous dysplasia.
 - amalgam tattoo.

ANS: C

Feedback	
A	Verrucous vulgaris is diagnosed on the basis of its clinical and microscopic appearance and does not require a radiograph.
B	Necrotizing ulcerative gingivitis requires clinical and historical data for diagnosis and does not require a radiograph.
C	Correct! Periapical cemento-osseous dysplasia requires a radiograph, specific patient history, and a pulp test to evaluate tooth vitality. It is frequently found in black women in the third decade of life.
D	An amalgam tattoo relies on clinical and historical data for diagnosis and does not require a radiograph.

REF: Historical Diagnosis, page 17 OBJ: 5

41. Leukoedema is a generalized opalescence appearing on the buccal mucosa; linea alba is a dark pigmented line appearing on the buccal mucosa.
- Both statements are true.
 - Both statements are false.
 - The first statement is true, and the second statement is false.
 - The first statement is false, and the second statement is true.

ANS: C

Feedback	
A	Leukoedema is a generalized opalescence appearing on the buccal mucosa, as stated, but linea alba is not a dark pigmented line.
B	The statement that leukoedema is a generalized opalescence appearing on the buccal mucosa is true; the statement that linea alba is a dark pigmented line is false. (Linea alba is a white line.)
C	Correct! The first statement is true, and the second statement is false.
D	Leukoedema is a generalized opalescence appearing on the buccal mucosa, but linea alba is not a dark pigmented line.

REF: Leukoedema, Figure 1-54, page 24 | Linea Alba, Figure 1-53, pages 23-24

OBJ: 8

42. Each of the following is considered a variant of normal except one. Which one is the *exception*?
- A. Melanin pigmentation
 - B. Linea alba
 - C. Geographic tongue
 - D. Retrocuspid papilla

ANS: C

	Feedback
A	Melanin pigmentation is commonly seen in dark-skinned individuals and is considered a variant of normal.
B	Linea alba is located on the buccal mucosa along the occlusal plane. It is most prominent in patients who have a clenching or bruxism habit. It is so common that it is considered a variant of normal.
C	Correct! Geographic tongue is characterized by diffuse areas devoid of filiform papillae. It is not a variant of normal.
D	Retrocuspid papilla is a sessile nodule on the gingival margin of the lingual aspect of the mandibular cuspids and is considered a variant of normal.

REF: Geographic Tongue, page 25 | Variants of Normal, pages 22-24

OBJ: 6

43. The term *erythroplakia* is best used in which of the following contexts?
- A. Microscopic
 - B. Laboratory
 - C. Surgical
 - D. Clinical

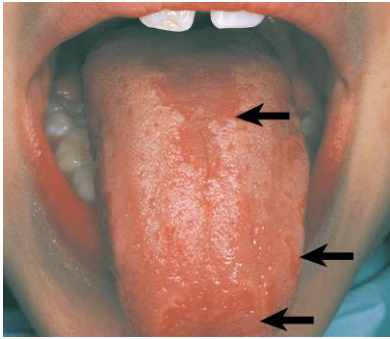
ANS: D

	Feedback
A	Microscopic diagnosis requires a biopsy.
B	Laboratory diagnosis involves the use of clinical laboratory tests, including blood chemistries and urinalysis.
C	Surgical diagnosis requires surgical intervention.
D	Correct! <i>Erythroplakia</i> is a descriptive clinical term for a red lesion.

REF: Vocabulary, Color of Lesion, page 2

OBJ: 9

44. This pathological lesion seen on the dorsal surface of the tongue is characteristic of:



- A. fissured tongue.
- B. hairy tongue.
- C. median rhomboid glossitis.
- D. migratory glossitis.

ANS: C

	Feedback
A	Fissured tongue is characterized by deep fissures or grooves.
B	Hairy tongue has the appearance of white, elongated filiform papillae.
C	Correct! Median rhomboid glossitis appears as a flat or slightly raised oval or rectangular erythematous area in the midline of the dorsal surface of the tongue.
D	<i>Migratory glossitis</i> is another name for geographic tongue and appears as patches on the lateral and dorsal surfaces of the tongue.

REF: Median Rhomboid Glossitis, page 24 | Figure 1-21, page 8
 OBJ: 7

45. Each of the following conditions is considered benign and of unknown cause except one. Which one is the *exception*?
- A. Hairy tongue
 - B. Amelogenesis imperfecta
 - C. Migratory glossitis
 - D. Fissured tongue

ANS: B

	Feedback
A	Hairy tongue is a benign condition of unknown cause.
B	Correct! Amelogenesis imperfecta represents a group of inherited conditions affecting the enamel of teeth.
C	Migratory glossitis is a benign condition of unknown cause.
D	Fissured tongue is a benign condition of unknown cause.

REF: Historical Diagnosis, page 16 OBJ: 7

46. A drug history of a patient taking a calcium channel blocker may reveal which of the following conditions?
- A. Gingival enlargement
 - B. Cementoma
 - C. Paget disease

D. Ulcerative colitis

ANS: A

	Feedback
A	Correct! A patient taking a calcium channel blocker may exhibit gingival enlargement.
B	A cementoma is not a result of a patient taking a calcium channel blocker.
C	An elevated serum alkaline phosphatase level is significant for Paget disease but not for use of a calcium channel blocker.
D	Ulcerative colitis may contribute to oral lesions but not gingival enlargement.

REF: Historical Diagnosis, Figure 1-39, pages 17-18

OBJ: 3

47. Urticaria is an example of a(n):
- A. genetic disorder.
 - B. developmental disturbance.
 - C. immediate response to an allergen.
 - D. immunodeficiency response.

ANS: C

	Feedback
A	Urticaria is not the result of a genetic disorder.
B	Urticaria is not the result of a developmental disturbance.
C	Correct! Urticaria is an immediate response to an allergen.
D	Urticaria is not a result of immunodeficiency.

REF: Historical Diagnosis, page 17

OBJ: 3

48. Which term is used to describe a lesion in which parts of a whole are joined together, or fused, to make one?
- A. Fissured
 - B. Coalescence
 - C. Diffuse
 - D. Multilocular

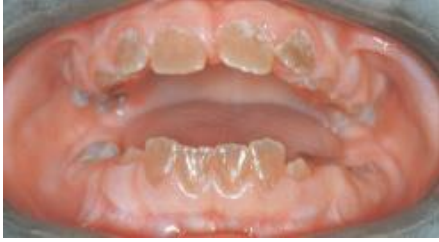ANS: B

	Feedback
A	<i>Fissured</i> describes a cleft or groove, normal or otherwise, showing prominent depth.
B	Correct! <i>Coalescence</i> describes the process by which parts of a whole join together, or fuse, to make one.
C	<i>Diffuse</i> describes a lesion with borders that are not well defined.
D	Multilocular lesions are described radiographically as “soap bubbles” (i.e., a lesion with many lobes beyond the confines of one distinct area).

REF: Vocabulary, Radiographic Terms Used to Describe Lesions in Bone, page 3

OBJ: 1

49. While obtaining diagnostic information from a patient, the dental hygienist learns that the appearance of this patient's teeth is familial. The correct diagnosis is:



- A. tetracycline staining.
- B. pulpal dysplasia.
- C. extrinsic staining.
- D. dentinogenesis imperfecta.

ANS: D

	Feedback
A	Tetracycline staining is not a familial condition.
B	Pulpal dysplasia is not a pathologic familial condition.
C	Extrinsic staining is not a familial condition.
D	Correct! Dentinogenesis imperfecta is a pathologic condition in which the family history plays a significant role in the diagnosis.

REF: Historical Diagnosis, Figure 1-38, pages 16-17

OBJ: 3

50. The eight categories that provide information leading to a definitive diagnosis are as follows: microscopic, clinical, laboratory, surgical, differential findings, radiographic, therapeutic, and:
- A. etiology.
 - B. historical.
 - C. chief complaint.
 - D. treatment.

ANS: B

	Feedback
A	Etiology is not a component of the definitive or final diagnosis.
B	Correct! Historical information reveals past experiences that may be relevant to the diagnosis.
C	The chief complaint may be helpful in understanding the patient's perspective but is not considered a diagnostic tool.
D	Treatment is decided after the definitive or final diagnosis is made, and it is not part of the information leading to the diagnosis.

REF: Making a Diagnosis, page 7

OBJ: 3